

SHORT COMMUNICATION

EFFECT OF SELENIUM DIOXIDE ON THE TESTES OF RAT

AMAL ROY CHOWDHURY AND H. VENKATAKRISHNA-BHATT

*Department of Histochemistry and Cytotoxicology,
National Institute of Occupational Health,
Meghani Nagar, Ahmedabad - 380 016*

(Received on February 16, 1983)

Summary : Selenium dioxide was administered (ip) to albino male rats (200 ± 5 g) in increasing doses (2, 6 and $10 \mu\text{g}/\text{rat}$, daily) for 90 days. Histologic and histometric study showed that there was dose dependent injury to testes. No cellular deformation was observed following $2 \mu\text{g}$ -dose; whereas $6 \mu\text{g}$ -dose caused significant damage of gametogenic cells. At a dose of $10 \mu\text{g}$, there was a significant testicular degeneration alongwith testicular atrophy.

Key words : testes

selenium dioxide

degeneration

INTRODUCTION

Selenium has long been known to have a damaging effect on different tissues of several species of animals (12, 2, 8). On the other hand, selenium is considered to be one of the most efficient protective agent against cadmium-induced injury (4, 5). Its effect on male reproduction however, has remained controversial (6, 7). Hence, the present study was undertaken to reexplore the effect of selenium dioxide on testes of the rat.

MATERIAL AND METHODS

Forty male Swiss albino rats (200 ± 5 g) were divided in 4 equal groups. Each group was kept under comparable climatic conditions ($75^\circ \pm 2^\circ\text{F}$) and husbandry during the study. Water was supplied *ad libitum*. The experimental groups (II, III, IV) were injected with selenium dioxide 2, 6 and $10 \mu\text{g}/\text{rat}$ (ip) daily for 90 days respectively. The control group (I) received only equivalent volume of normal saline (0.9% NaCl, 0.5 ml).

All rats were sacrificed by cervical dislocation on the 91st day. Testes on both sides were weighed and fixed in Boun's fluid; $5 \mu\text{m}$ paraffin sections were cut and stained

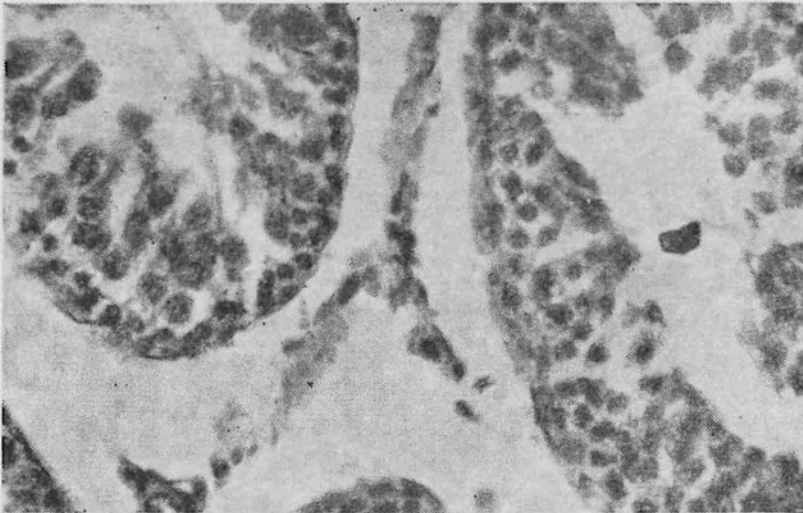


Fig. 1 : Partial degeneration of the seminiferous tubules and normal Leydig cells in the rat following treatment with SeO_2 ($6 \mu\text{g}$, ip, every day) for 90 days. (X 640).

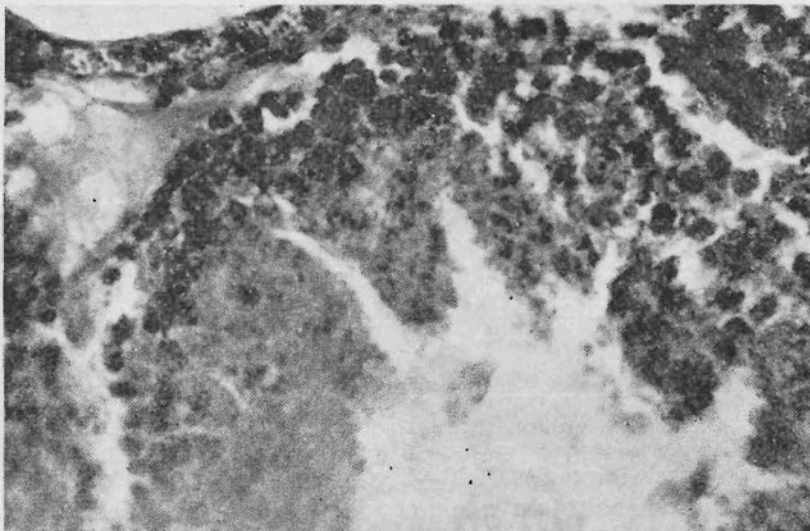


Fig. 2 : Complete testicular degeneration of cellular elements in the rat following treatment with SeO_2 ($10 \mu\text{g}$, ip, every day) for 90 days. (X 640).

with iron hexatoxylene and eosine. The seminiferous tubular diameter was measured with ocular micrometer at 160 X magnification (8). The nuclear diameter and number

of Leydig cells per field was counted at 640 X magnification (11). Student 't' test was employed for statistical analysis.

RESULTS AND DISCUSSION

The cellular structure of testes was no way abnormal in control group (group I). Similarly, group II did not exhibit alternations in cellular orientation and testicular weight. Significant decrease in testicular weight was noted in group III. Mild degeneration of gametogenic cells was obvious, though Leydig cell structure was unaltered (Table I, Fig. 1). Severe changes were found in group IV animals with testicular atrophy and the degeneration of testicular tissues (Fig. 2). The deformed embryo and infertility in rats and mice were also reported in chronic and acute toxicity of selenium (9, 10). Moreover, earlier it was reported, that feeding of selenium at 7.5 ppm level prevented reproduction in females (13). From this viewpoint it is interesting that selenium affords protection in cadmium intoxicated rats, including that against testicular damage (12). In the present study, rats were chronically exposed to SeO₂ over 90 days period. The 2 µg-dose had no apparent effect, whereas the change with 6 µg-dose was moderate. It might be possible that testosterone synthesis in rats given 6 µg-dose was unaltered since Leydig cells appeared to be normal. On the other hand, 10 µg-dose caused profuse degeneration in testicular tissue. Therefore, our finding suggests that the action of SeO₂ on testes is seen only after a certain dose-level is reached.

TABLE I : Effect of selenium dioxide (given ip, daily, for 90 days) on testicular mass, seminiferous tubular diameter, Leydig cell nuclear diameter and Leydig cell population. Values are means ± S.E.M. (number of the observations in paranthesis)

Group*	Treatment	Absolute weight (g) (10) of testes	Relative weight of testes (mg/100 gm body weight) (10)	Seminiferous tubular diameter (µm) (20)	Leydig cell nuclear diameter (µm) (20)	Leydig cell nuclear population/per field
I	Control	1.110 ± 0.09	679 ± 25.40	190.40 ± 5.27	5.70 ± 0.37	8.24 ± 1.02
II	2 µg SeO ₂ /rat	1.090 ± 0.12 ^{NS}	674 ± 23.42 ^{NS}	190.78 ± 4.27 ^{NS}	6.00 ± 0.21 ^{NS}	8.00 ± 1.22 ^{NS}
III	6 µg SeO ₂ /rat	0.942 ± 0.22 ^a	531 ± 21.4 ^a	156.00 ± 3.87 ^a	5.87 ± 0.34 ^{NS}	5.23 ± 0.96 ^a
IV	10 µg SeO ₂ /rat	0.721 ± 0.34 ^b	442 ± 12.40 ^b	152.32 ± 4.32 ^a	5.62 ± 0.49 ^{NS}	3.90 ± 0.61 ^a

*Each group had 10 rats.

Value differs significantly from the control (a; P < 0.05, b; P < 0.001, NS; not significant, t-test)

ACKNOWLEDGEMENTS

The authors thank Dr. B.B. Chatterjee, Director, NIOH, Ahmedabad, for his critical suggestions in the study.

REFERENCES

1. Cantor, A.H., P.D. Moorhead and K.I. Brown. Influence of dietary selenium upon reproductive performance of male and female breeder turkeys. *Poultry Science*, **57** : 1337-1345, 1978.
2. Diplock, A.T. Metabolic aspects of selenium action and toxicity. *Crit. Rev. Toxicol.*, **4** : 271-329, 1976.
3. Gunn, S.A., T.C. Gould and W.A.D. Anderson. Mechanisms of Zinc, cysteine and selenium protection against cadmium induced vascular injury to mouse testes. *J. Reprod. Fert.*, **15** : 65-70, 1968.
4. Gunn, S.A., T.C. Gould and W.A.D. Anderson. The testis III influencing factor. (Johnson A.D., W.R. Gomes and A.D. Vandemark Eds. Academic Press, New York, pp 423-430, 1970.
5. Halverson, A.W., I.S. Palmer and P.L. Guss. Toxicity of selenium to post weanling rat. *Toxicol. Appl. Pharmacol.*, **9** : 477-484, 1966.
6. Kar, A.B. and R.P. Das. The nature of protective action of selenium on cadmium induced degeneration of rat testis. *Proc. Natl. Inst. Sci., India*, **B 29** : 297-305, 1963.
7. Kurzel, R.B. and C.L. Cetrulo. The effect of environmental pollutants on human reproduction, including birth defects. *Environ. Sci. Technol.*, **15** : 627-639, 1981.
8. Moxan, A.L. and M. Rhian. Selenium poisoning. *Physiol. Rev.*, **203** : 305-337, 1943.
9. Niewenhuis, R.J. and P.L. Fende. The protective effect of selenium on cadmium induced injury to normal and cryptorchid testes in the rat. *Biol. Reprod.*, **19** : 1-7, 1978.
10. Rosenfeld, I. and O.A. Beath. The influence of various substances on chronic selenium poisoning. *J. Pharmac. exp. Ther.*, **91** : 218-223, 1947.
11. Roy Chowdhury, A. and A.K. Chatterjee. Effect of adrenalectomy on the testicular cells of immature rats. *Ind. J. Expt. Biol.*, **16** : 88-89, 1978.
12. Schroeder, H.A. Selenium and tellurium in mice. *Arch. Environ. Health.*, **24** : 66-71, 1972.
13. Smith, M.I. Chronic endemic selenium poisoning. *J. Am. Med. Ass.*, **116** : 562-567, 1941.